



**PRESENTING CLINICAL SIGNS**

History: Presented for tachycardia, abdominal retracting. History of CHF. Receiving furosemide 6.25 mg BID, pimobendan 1.25 mg BID, and spironolactone 12.5 mg BID. On and off anorexia, labored breathing. History of dry hacking cough, deviated trachea.

DATE

7/8/22

**ECHOCARDIOGRAPHIC FINDINGS**

2D, M-mode, and Doppler study.

PERFORMED BY:

Kelly Vazquez

There is severe left atrial dilation. The mitral valve leaflets are thickened and exhibit systolic prolapse. A severe jet of eccentric mitral regurgitation is present. There is severe left ventricular dilation. Left ventricular systolic function is mildly hyperdynamic. The aorta and aortic valve appear normal, though trace aortic insufficiency is present. Right atrial and right ventricular dimensions are normal. The tricuspid valve is normal. The pulmonary artery and pulmonic valve are normal. No shunting lesions are visualized. No pericardial effusion or cardiac masses are seen.

INTERPRETED BY

Keith Blass, DVM,  
MS, DACVIM  
(Cardiology)

LA - 35.5 mm  
LVIDd - 35.5 mm  
LVIDs - 20.5 mm  
FS - 42%  
LVOT - 1.22 m/s  
RVOT - 1.09 m/s

PATIENT

Luna Lauretta

**ASSESSMENT/RECOMMENDATIONS**

Degenerative mitral valve disease

SPECIES

Canine

This examination demonstrates severe regurgitation of blood across Luna's mitral valve resulting from degenerative valve disease. Secondary to her regurgitation, Luna has severe dilation of both her left atrium and left ventricle, though her left ventricular systolic function is well-preserved.

BREED

Chihuahua

Given the severity of her disease, I'm concerned that Luna's abdominal breathing is due to the recurrence of left-sided congestive heart failure and that her tachycardia is a compensatory response to maintain an adequate cardiac output, however, thoracic radiographs and an ECG are recommended for further evaluation.

SEX

FS

If congestive heart failure is present, I recommend increasing Luna's furosemide dose to at least 12.5 mg BID, as well as starting her on enalapril (1.25 mg BID, if renal function adequate). I also recommend lowering Luna's spironolactone dose to 6.25 mg BID if she is currently receiving 12.5 mg BID.

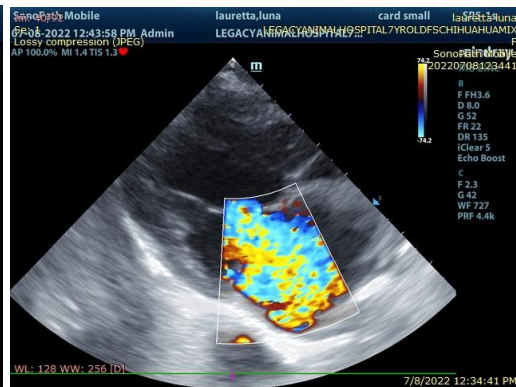
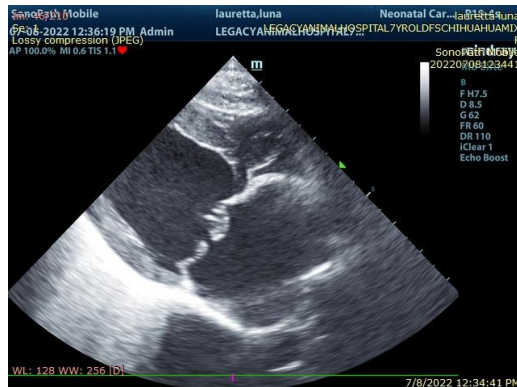AGE

7 y

Recheck radiographs and a renal/electrolyte profile are recommended in 1 week if Luna's cardiac medications are adjusted. A recheck echocardiogram is recommended in 6-9 months.

WEIGHT

9.2 lb



HOSPITAL NAME

Legacy AH

REFERRING VET

Dr. Pontezzone



DATE

7/8/22

The information and recommendations provided are based on the images presented by the referring veterinarian. No evaluation can be communicated regarding pathology that was not visible in the image/video clips provided.

PERFORMED BY:

Kelly Vazquez

Thank you for this referral. If the clinical or image interpretation does not parallel your findings or if I can be of any further assistance please contact me.

INTERPRETED BY

Keith Blass, DVM,  
MS, DACVIM  
(Cardiology)

**Keith Blass, DVM, MS, DACVIM (Cardiology)**  
KeithBlass@gmail.com  
631-804-5754

PATIENT

Luna Lauretta

SPECIES

Canine

BREED

Chihuahua

SEX

FS

AGE

7 y

WEIGHT

9.2 lb

HOSPITAL NAME

Legacy AH

REFERRING VET

Dr. Pontenzone